Revascularization of non-vital immature teeth – a case report

▲Wan-Ru Fu[1], Szu-Yu Hsiao[1], Hong-Sen Chen [1,2]

[1]*Division of pediatric dentistry, Department of dentistry, Kaohsiung Medical University Hospital, Kaohsiung Medical University, Kaohsiung, Taiwan*

[2]*Department of Oral Hygiene, College of Dental Medicine, Kaohsiung Medical University, Taiwan*

Introduction

Endodontic treatment of immature necrotic teeth usually meets many difficulties in children, because those teeth have open root apex, thin root dentin, large canal lumen and are prone to fracture. This kind of endodontic treatment is a challenge until recently; a biologically based treatment called revascularization/regeneration now allows for complete root development.

Case report

A 10-year-old Asian boy had a history of extra cusp (accessary cusp) fracture involving the pulp on tooth 45. Clinical and radiographic examinations revealed that the mandibular right 2nd premolar had percussion pain, and the root was immaturely developed and the pulp is necrotic with apical periodontitis. Revascularization was performed via the following steps: After local anesthesia, rubber dam isolation, and access cavity preparation, the tooth was irrigated with 20ml of NaOCl 5.25% and received triple antibiotic dressing(metronidazole, ciprofloxacin, minocycline) for 2 weeks. On the next visit, patient has no present symptoms and signs, and bleeding was induced inside the canal, and then the coronal thirds of the canals were sealed with mineral trioxide aggregate, then permanently restored with composite resin. In clinical and radiographic follow-up, the tooth was functional, the periapical lesions were healed, and the apex have formed, but the crown part become gray black, the tooth 45 discolored. On the six months follow-up, the electronic pulp test over tooth 45 is positive, this revealed that the vitality is recovering.

Fig A: Original film shows extra cusp fracture and has PAP over tooth 45 root apical . Fig B: Open chamber and triple antibiotic dressing. Fig C: Induce bleeding and sealed with MTA. Fig D: One month follow-up, the size of PAP decreased. Fig E: Four months follow-up, PAP over root apical disappeared. Fig F: Six months follow-up, apex have formed.

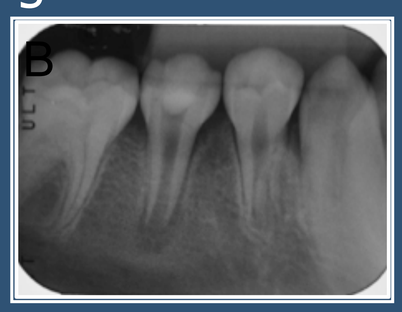

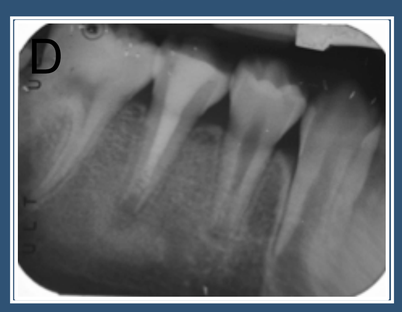

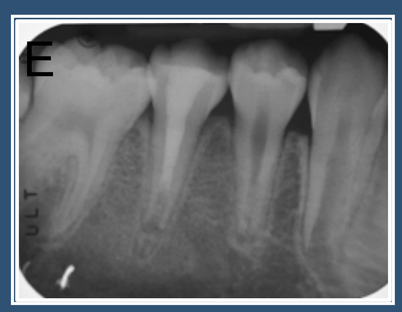

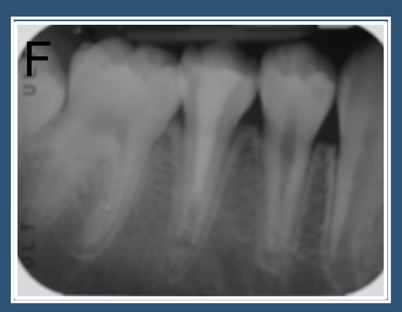

Comments

For immature teeth with pulp necrosis and apical periodontitis, revascularization/regeneration procedures were encouraged to grow new pulps and complete the root formation (for length and wall thickness). Regeneration of pulp-like tissue is possible after revascularization; both the apical papilla and the Hertwig's epithelial root may survive in an immature permanent tooth - even with pulpal necrosis and apical periodontitis.

Fig G is original clinical photo, Fig H is nine months follow-up clinical photo. The color become grayer than original.