Prevention of spontaneous abscesses from permanent teeth in x-linked hypophosphataemia

Mihiri Silva[1,2], David Manton[1,2], Kerrod Hallett[1,2], Luke Moloney[1], Simon Watson[1]

[1] Royal Children's Hospital, Melbourne, Australia [2] Melbourne Dental School, The University of Melbourne, Australia,

Introduction

With an incidence of 1 in 20,000, X-linked hypophosphatemia (XLH) is a X-linked dominant genetic disorder caused by mutations in the PHEX gene [1,2]. In children with a known family history of XLH, the condition is often diagnosed in the first year of life [3]. Without treatment, progressive bow deformities of the lower legs, short stature and rickets may be evident by 2-3 years of age. The most well recognised dental complications are spontaneous dental abscesses which occur without evidence of dental caries or a history of trauma [4]. Abscesses are believed to be due to abnormal mineralisation and clefts in dentine and enlarged pulp chambers with large pulp horns extending to the dentino-enamel junction(DEJ) [5]. The communications between the DEJ and the pulp may allow bacterial ingress and pulpal necrosis, particularly when tooth wear compromises the enamel layer. Although medical therapy may improve dental structure and oral health outcomes, dental abscesses and complications have been reported to affect patients even with very early medical intervention. In order to minimise the risk of dental abscesses on molar teeth, protection of the occlusal surfaces of primary and permanent molars is often indicated [4]. Stainless steel crowns without tooth preparation may protect the teeth from bacterial ingress, but are unaesthetic and may lead to periodontal complications later in life. Occlusal coverage with direct flowable composite resin has also been reported, but requires frequent replacement due to poor wear resistance [6]. There is currently no ideal restoration for prophylactic use in children with x-linked hypophosphataemic rickets at risk of dental abscesses.

Case report

An eleven-year-old boy presented to the dental department of the Royal Children's Hospital, Melbourne (RCH) in August 2011 for a follow-up assessment, two months after having emergency endodontic treatment for dental abscess from his two lower permanent central incisors. The patient had XLH and had undergone multiple surgical interventions for lower limb abnormalities due to rickets. The patient had attended the RCH Dental Department from five years of age and was originally referred for management of spontaneous abscesses from his primary teeth. He has undergone extensive dental treatment under GA (Table 1). In early 2011 the patient had a fall on a scooter and suffered concussion of all four central incisors and enamel infractions of teeth 11 and 21. Due to the mild nature of the injury, no treatment was deemed necessary. However, endodontic therapy was necessary two months later after both lower central incisors developed pulpal necrosis.

Table 1 Past dental history

Year	Age	
2004	5	• Private dental clinic due to dental abscess
2005	5	• Attends RCH Dentistry • Dental abscess 55, 54, 51 • Draining sinus 74, 84 • GA: Extraction of 55,54,51,64,74,84 & SSC (65, 75, 85)
2006	6	• Extraction of 65 due to dental abscess • Fissure sealants
2010	10	• URA for correction of anterior cross-bite (12/42)
2011	11	• Concussion 11,21,31,41 • Enamel infractions 11,21 • Dental abscess 31, 41 • Endodontic therapy commenced 31,41

Clinical and radiographic examination

Table 2 Clinical and radiographic findings

Examination	
Clinical examination	• Healthy permanent dentition • Temporary restoration 31,41
Radiographic examination	• 18, 28,38, 48 unerupted • PA radiolucency 31,41 • Enlarged pulp chambers / Taurodontism

Figure 1. OPG

Clinical management

The first stage of treatment involved completion of endodontic therapy on both lower central incisors. All fully erupted permanent posterior teeth were then restored with indirect composite onlays (Steps 1 -5).

Steps 1 & 2: Alginate Impressions and Bite registration; Wax-up on articulator

A bite registration was taken with an arbitrary bite opening of 2.5mm anteriorly, allowing space posteriorly for composite onlays of approximately 1 mm thickness.

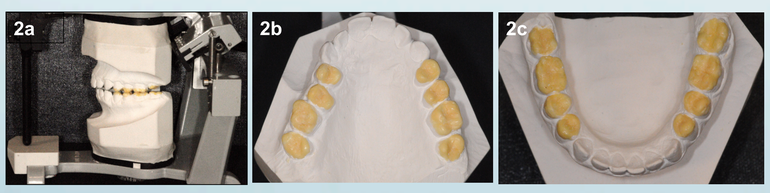

Figures 2 a, b, c Wax-up after mounting on articulator

The bite registration was transferred to an articulator for wax-up (Figure 2a,b,c).

Step 3: Clear suck-down trays

The waxed-up models were duplicated and clear suck-down trays were fabricated (Figure 3a,b).

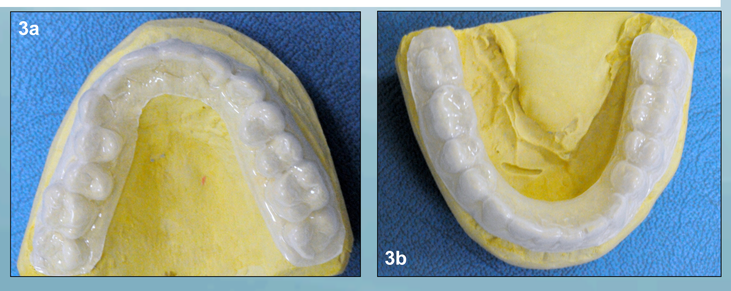

Figure 3a, b, Clear suck-down trays on duplicate models

Step 4: Fabrication of indirect composite onlays

Composite onlays were made by placing composite resin (B1; Gradia, GC Corp, Japan) into the suck-down trays and seating the trays on the original models (Figure 4a-c). After light curing for 40 seconds, the composite was removed from the trays and polished into individual onlays using abrasive discs.

Figure 4a, b, c Fabrication of indirect composite onlays

Step 5: Cementation of composite onlays

Figure 5a,b Immediately following cementation of composite onlays

The onlays were cemented, one quadrant at a time, over a series of four appointments (Figure 5a,b).

Under rubber dam isolation, the teeth and onlays were etched (Ultradent Inc, USA) and bonded (Singlebond, 3MEspe, MN, USA) and cemented with flowable composite (Wave, SDI, Melbourne, Australia). Excess flowable composite was polished.

- The upper incisors were sealed with the same flowable composite.
- The placement of the restorations led to a increase in occlusal vertical dimension and an anterior open bite of 1mm however the patient was warned about the changes to his occlusion, and adapted well.

Follow up – 12 months

The patient was reviewed 3-monthly and the anterior open bite corrected within three months. At the nine month review, There was a small fracture of the overlay restoration on tooth 46 and a minimally invasive approach was employed to repair the defect directly with composite resin. At the 12-month follow up, the restorations were stable. The anterior open-bite had also resolved with a current overbite of 1mm.

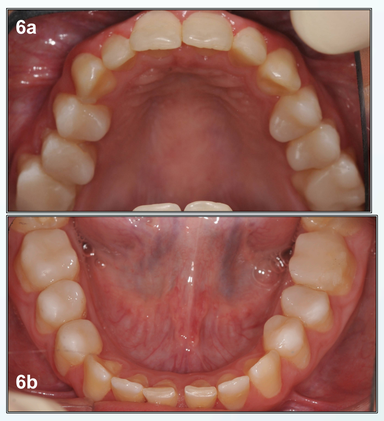

Figure 6 a,b 12-month follow up

Comment

- This case demonstrates successful prevention of spontaneous dental abscesses in a child with XLH. Due to the rarity of the condition, current protocols for management of the condition are based on case series. Although the technique has yielded excellent results over a twelve-month review period, longer-term results and further applications are needed.
- Despite the limitations, this technique is superior to previously used alternatives as it is relatively easy to place, aesthetic, cost-effective, periodontally sound and minimally invasive.
- Unlike direct restorations, the indirect technique allows for predictable changes to the occlusion. In addition, extra-oral fabrication of composite onlays reduces chair-side time and therefore better tolerated by young patients. The restorations have better wear resistance than flowable composite and have not required replacement due to wear yet.
- In addition, they provide a more aesthetic and periodontally sound alternative to stainless steel crowns, which due to sub-gingival margins that can compromise periodontal health, eventually require replacement with conventional materials. Conventional crowns and onlays are not indicated in healthy teeth of young patients with XLH due to the need for removal of healthy tooth structure, the risk of pulpal necrosis during tooth preparation and issues with patient cooperation.

References

1. Alizadeh Naderi, A.S. and R.F. Reilly, Hereditary disorders of renal phosphate wasting. Nature reviews. Nephrology, 2010. 6(11): p. 657-65.
2. Pettifor, J.M., What's new in hypophosphataemic rickets? European journal of pediatrics, 2008. 167(5): p. 493-9.
3. Carpenter, T.O., The expanding family of hypophosphatemic syndromes. Journal of Bone and Mineral Metabolism, 2012. 30(1): p. 1-9.
4. Seow, W.K. and S.C. Latham, The spectrum of dental manifestations in vitamin D-resistant rickets: implications for management. Pediatric dentistry, 1986. 8(3): p. 245-50
5. Pereira, C.M., et al., Dental alterations associated with X-linked hypophosphatemic rickets. Journal of Endodontics, 2004. 30(4): p. 241-245
6. Douyere, D., et al., Familial hypophosphatemic vitamin D-resistant rickets-prevention of spontaneous dental abscesses on primary teeth: A case report. Oral Surgery Oral Medicine Oral Pathology Oral Radiology and Endodontology, 2009. 107(4): p. 525-530.